

Case Report

An unusual case of neglected bilateral isolated aplasia of the patella in a 21-year-old patient: A case report

Cuneyd Gunay^{a,*}, Hakan Atalar^b^a Department of Orthopaedic Surgery and Traumatology, Yunus Emre State Hospital, Eskisehir, Turkey^b Department of Orthopaedic Surgery and Traumatology, Gazi University, Ankara, Turkey

ARTICLE INFO

Article history:

Received 19 July 2012

Received in revised form

16 August 2012

Accepted 12 September 2012

Available online 20 February 2013

Keywords:

aplasia

neglected

patella

ABSTRACT

Isolated absence of the patella is an extremely rare condition. Absence or hypoplasia of the patella is usually associated with genetic disorders and lower limb malformations. In this paper, an isolated absence of the patella without any other deformities is described. A 21-year-old male patient referred to our clinic presented with walking difficulty in the past 6 months and deformity of both knees. Except for these complaints, he had no problems. Isolated aplasia of the patella may cause no major dysfunction, and surgical or major treatment is not always required. The most interesting point of this case is that the patient had not experienced any complaints for over 20 years, nor was he aware of his knee deformity. This appears to be the first report of neglected bilateral patellar aplasia in a 21-year-old male patient. Copyright © 2013, Taiwan Orthopaedic Association. Published by Elsevier Taiwan LLC. All rights reserved.

1. Introduction

The patella is the largest sesamoid bone in the skeleton. It is a somewhat triangular-shaped sesamoid bone that is wider at the proximal than the distal pole. The articular surface of the patella is divided by a vertical ridge, resulting in a smaller medial and a larger lateral articular facet. The patella protects the ventral cartilaginous surfaces of the knee joint. It is located within the tendon of the quadriceps femoris muscle, the main role of the patella being to facilitate the extensor function of the quadriceps muscle.

Congenital absence of the patella is a very rare condition but is often observed bilaterally and associated with other malformations such as congenital dislocation of the hip, talipes equinovarus, and nail–patella syndrome (NPS). Occasionally it presents as an isolated lesion.^{1–3} The prevalence rate of patellar hypoplasia or aplasia in the newborn child is not available, and is difficult to obtain because the patella is completely cartilaginous at birth and starts its ossification process between approximately the third and the sixth year.¹ In this case, we reported a neglected bilateral congenital patellar syndrome in a 21-year-old male patient.

2. Case report

A 21-year-old male farmer was referred to our clinic with complaints of deformity of both knees and walking difficulty in the past 6 months. From his history, besides his knee deformity, in the last 6 months he had sometimes difficulties with long-distance walking after 1 hour. In addition, he had night pains after working hard on the farm. Except for these complaints, he had no problems. He was able to straighten both knees, and he had no problem at upright position. No recognizable symptoms or disabilities were observed in the affected knees, and the patient was able to play high-impact sports activities including football, run, and so on.

On further questioning, we also found out that his developmental milestones were normal, and he had had no deformity of the knees at birth. His father had three other children (two boys and one girl) besides our patient. Each family member was examined, and no problems were observed. As far as they could recall, they had no blood relatives with any abnormality of their knees or any fingernail problems.

The patient was seen in the internal medicine department for careful systemic examination. His report revealed normal renal function and no abnormality of the kidneys. The rest of his blood parameters were within normal limits. Under physical examination, knee flexion was 110 degrees, extension was 0 degrees, both internal and external rotation were 10 degrees, and no flexion contracture or joint effusion was observed. The gliding position of

* Corresponding author. Department of Orthopaedic Surgery and Traumatology, Yunus Emre State Hospital, Uluönder Mahallesi Salih Bozok Caddesi No. 23, 26190 Tepebasi, Eskisehir, Turkey. Tel.: +90 222 335 06 50; fax: +90 222 335 20 41.

E-mail address: cungunay@hotmail.com (C. Gunay).

the quadriceps tendon during knee flexion and extension was normal. The knees were stable to valgus and varus stress tests, anterior and posterior drawer tests, and also the Lachman test. No muscle atrophy was seen. Quadriceps muscle strength was noted to be 5/5. The patient's limb lengths were measured and were equal on both sides. Both medial femoral condyles were more prominent than the lateral femoral condyles, and the anterior aspect of the knee was flattened, which was more evident when the knee was flexed (Fig. 1). On clinical examination, a bilateral absent patella and a hollow sulcus were seen in between the femoral condyles (Fig. 2). There was no nail dystrophy.

Radiographs of the pelvic bones and elbows, other skeletal examination, and range of motion were normal. Radiographic evaluation (anteroposterior, lateral, and tunnel radiographs) showed absence of both patellas, both trochleas to be hypoplastic (Fig. 3), and overhanging medial femoral condyles with narrow medial tibial plateaus on the anteroposterior views, with slight lateral subluxation of the both tibias.

We prescribed oral nonsteroidal anti-inflammatory drugs for analgesia, although the patient was already using these drugs. His pain was relieved by the medications, and he continued his daily and sports activities. Follow-up was for 1 year, at 3-monthly intervals. As the case was uncommon, the patient signed a specific informed consent for the scientific use of his data.

3. Discussion

Human developmental syndromes with patellar malformations may be caused by single-gene defects or result in major characteristics of a number of disorders, including NPS, small patella syndrome, Meier–Gorlin syndrome, Rapadilino syndrome, genitopatellar syndrome, aniridia, and trisomy 8q syndrome.¹ The most common syndrome with congenital patellar hypoplasia or aplasia and defective dorsoventral limb patterning is NPS. Patients with NPS present with dysplastic nails, absent or hypoplastic patellas, elbow dysplasia, exostoses of the ilia, swan-neck deformity and absent skin creases on the dorsal aspect of the distal interphalangeal joints of the fingers, tingling, numbness, and in some cases renal insufficiency.

Onycho-osteodysplasia (NPS) is transmitted as a simple autosomal dominant gene. There is a definite linkage between the locus of the nail–patella gene and the ABO blood groups.^{1,4,5} Thus, we

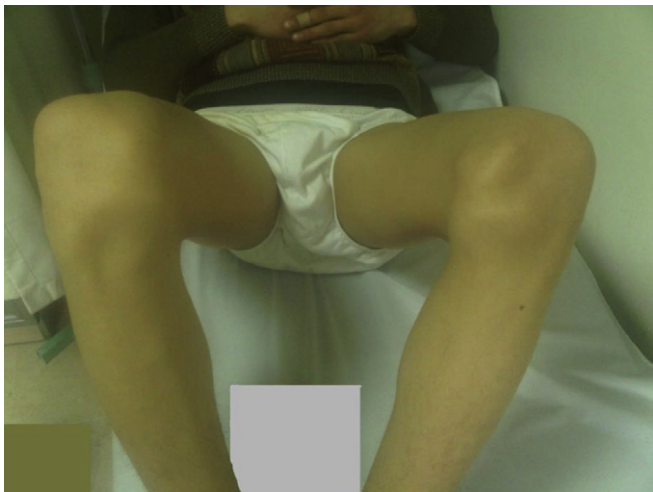

Fig. 1. Clinical picture showing more prominent medial femoral than lateral femoral condyles.

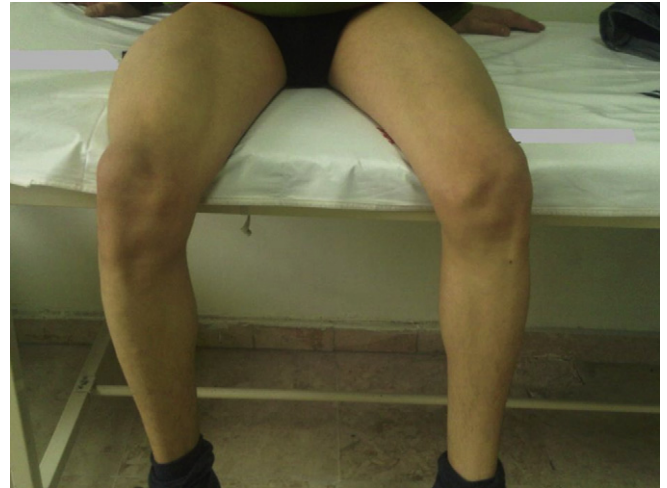


Fig. 2. Clinical picture of bilateral absence of the patella.

examined our patient for NPS but we did not observe any deformities or ABO blood group defects, except for bilateral patellar aplasia. *LMX1B* is a unique mesenchymal determinant of dorsal patterning during vertebrate limb development, so mutations in the *LMX1B* gene result in skeletal dysplasia affecting the dorsal tissues, especially the nails and patellas.⁶ Our patient's genetic pattern was not determined.

Congenital patellar syndrome is described as bilateral isolated absence of the patella. Generally, congenital patellar hypoplasia or aplasia is associated with various genetic disorders and a heterogeneous group of lower limb malformations. Congenital malformations of the patella can be seen as complete agenesis (patellar aplasia) or underdevelopment of the entire patella resulting in a small size of the patella (patellar hypoplasia).⁷ In addition to radiographic examination of the knee, pelvis, and feet, X-rays should be ordered for every patient presenting with patellar aplasia or hypoplasia to help to establish an accurate diagnosis for the small patella syndrome.⁸ Accordingly, we evaluated other parts of the body but could not find any anomaly on X-ray.

MRI of the knee can also be ordered if patients are not able to extend their knees and/or their quadriceps strength is below normal during the physical examination. In our opinion, our physical examination, the patient's history, and the plain X-ray findings were adequate to rule out a need to look for any extra findings on MRI.

Previously, it has been suggested that small patella syndrome might be allelic to isolated patella aplasia–hypoplasia.¹ Patella aplasia–hypoplasia is a rare autosomal dominant disorder in which congenital aplasia or hypoplasia of the patella is the only clinical and radiographic sign.^{1,9} We assume that our case is of an isolated patella aplasia–hypoplasia disorder because we did not detect any abnormalities in our patient or in his family.

Two similar cases of aplasia of the patella have been reported (Table 1). In 1949, Kutz³ reported the case of a 9-year-old girl with congenital absence of the patella with no other clinical and radiographic abnormalities. This was the first report of isolated patella aplasia–hypoplasia. Jerome et al² reported another case of a congenital patellar syndrome in 2009. In 1963, Bernhang and Levine¹⁰ first described a familial occurrence of isolated patella aplasia–hypoplasia.

If absence of the patella is associated with atrophy of the quadriceps mechanism, patients will have weakness of knee extension and will develop progressive flexion deformity of the knee. They

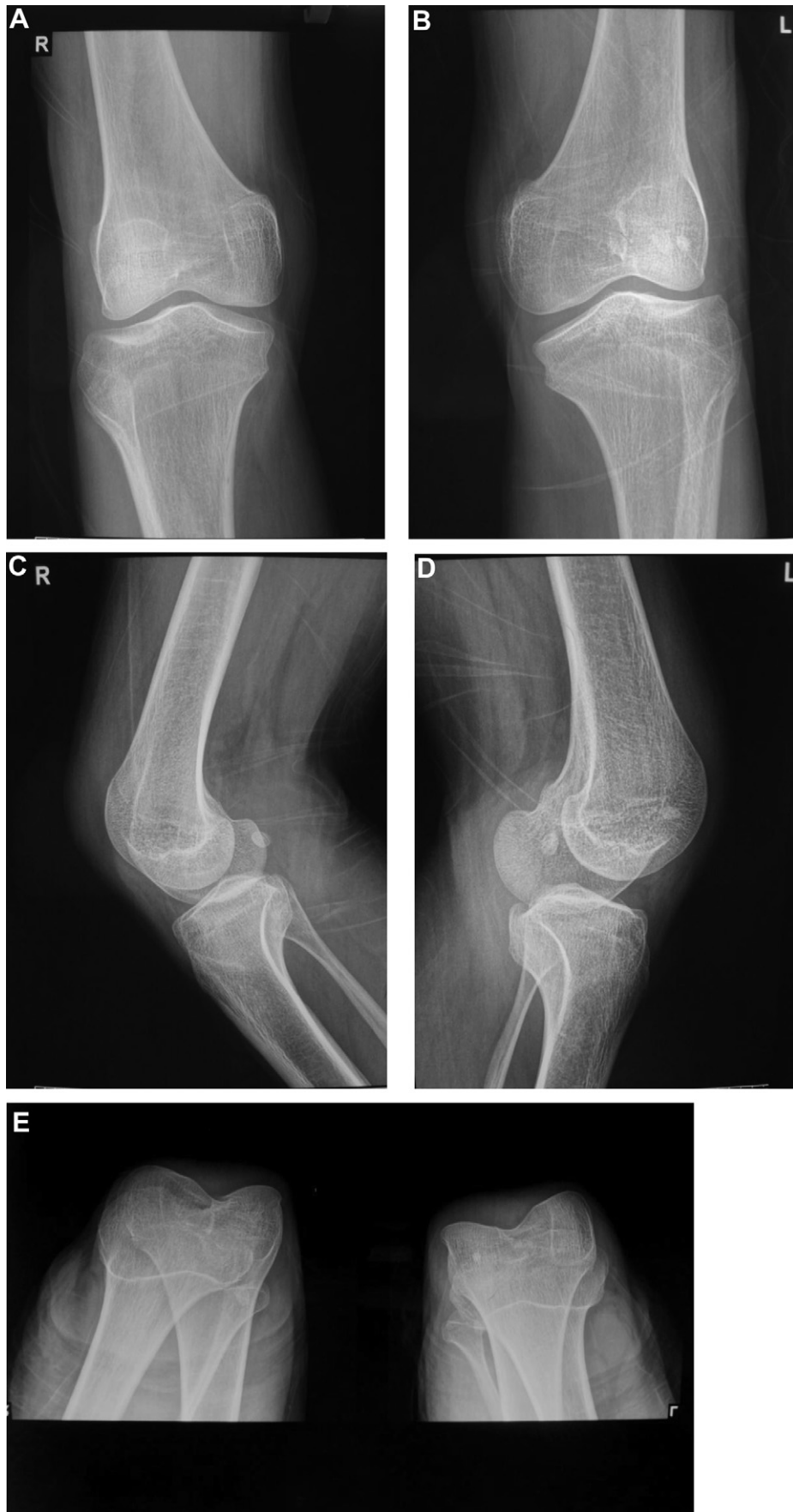

Fig. 3. Anteroposterior (A,B), lateral (C,D) and tunnel (E) radiographs of bilateral absence of the patella.

Table 1

The clinical features of reported isolated aplasia of the patella.

	Kutz ³	Jerome et al ²	Present case
Age at presentation	9 years	9 years	21 years
Sex	Female	Male	Male
Symptoms at presentation	Inability to straighten the knee and walking difficulty	Deformity in both knees and difficulty in the standing position	Deformity in both knees and walking difficulty

complain about difficulties with running, climbing the stairs, riding a bike, and stopping abruptly, and often have knee instability. During childhood, some experience unexpected falls while walking, without additional problems. Conversely, disability is minimal if the quadriceps mechanism is intact. For example, In Jerome's² report the patient have complaints of difficulty in standing and walking may be because of inefficient quadriceps mechanism.

The interesting point in our case was that our patient was asymptomatic for 20 years, and his complaints had started slowly in the previous 6 months. He was a farmer living in a small village, and his lack of complaints for 20 years was most likely due to his strong quadriceps muscles. A previous study¹¹ reported that one of the patients who was diagnosed with hypoplastic patella with NPS at the age of 2 years needed no surgical treatment. At the age of 22, she occasionally complained about her knee pain.

In the present case, the patient's knees were stable. The joint compressive load and quadriceps force significantly decrease total translation by as much as 50–66% in knees with intact anterior cruciate ligaments. The primary dynamic restraint is the quadriceps muscle. The quadriceps is usually strong and glides in the patellar groove between the femoral condyles in congenital patella aplasia or hypoplasia.^{8,12,13} Treatment consists of exercises to develop quadriceps motor strength. If quadriceps motor function is poor, the medial and lateral hamstrings are transferred laterally to provide active knee extension. In our patient there were no complaints regarding quadriceps muscle motor strength, so our only treatment was oral nonsteroidal anti-inflammatory drugs. During childhood, it can be difficult to detect absence of the patella because of its ossification pattern. In cases with normal quadriceps muscle strength, the patellar aplasia may go undetected and treatment is not always required.

4. Conclusions

Isolated aplasia of the patella may cause no major dysfunction, and surgical or major treatment is not always required. The most interesting point of this case is that this patient had neither experienced any complaints for 20 years, nor had he been aware of his knee deformity. This makes our case a unique neglected isolated patella aplasia–hypoplasia disorder in the literature.

Competing interests

The authors declare that they have no competing interests.

References

1. E.M. Bongers, A. van Kampen, H. van Bokhoven, N.V. Knoers. Human syndromes with congenital patellar anomalies and the underlying gene defects. *Clin Genet* 68 (2005) 302–319.
2. J.T. Jerome, M. Varghese, B. Sankaran. Congenital patellar syndrome. *Rom J Morphol Embryol* 50 (2009) 291–293.
3. E.R. Kutz. Congenital absence of the patellae. *J Pediatr* 34 (1949) 760–762.
4. E.M. Bongers, F.T. Huysmans, E. Levtschenko, J.W. de Rooy, J.G. Blickman, R.J. Admiraal, P.L. Huygen, et al. Genotype-phenotype studies in nail-patella syndrome show that LMX1B mutation location is involved in the risk of developing nephropathy. *Eur J Hum Genet* 13 (2005) 935–946.
5. J.A. Dunston, T. Reimschisel, Y.Q. Ding, E. Sweeney, R.L. Johnson, Z.F. Chen, I. McIntosh. A neurological phenotype in nail patella syndrome (NPS) patients illuminated by studies of murine Lmx1b expression. *Eur J Hum Genet* 13 (2005) 330–335.
6. S.D. Dreyer, R. Morello, M.S. German, B. Zabel, A. Winterpacht, G.P. Lunstrum, W.A. Horton, et al. LMX1B transactivation and expression in nail-patella syndrome. *Hum Mol Genet* 9 (2000) 1067–1074.
7. J. Spranger, K. Benirschke, J.G. Hall, W. Lenz, R.B. Lowry, J.M. Opitz, L. Pinsky, et al. Errors of morphogenesis: concepts and terms. Recommendations of an international working group. *J Pediatr* 100 (1982) 160–165.
8. F. Dellestable, P. Péré, A. Blum, D. Régent, A. Gaucher. The 'small-patella' syndrome. Hereditary osteodysplasia of the knee, pelvis and foot. *J Bone Joint Surg Br* 78 (1996) 63–65.
9. M. Mangino, O. Sanchez, I. Torrente, A. De Luca, F. Capon, G. Novelli, B. Dallapiccola, et al. Localization of a gene for familial patella aplasia-hypoplasia (PTLAH) to chromosome 17q21–22. *Am J Hum Genet* 65 (1999) 441–447.
10. A.M. Bernhang, S.A. Levine. Familial absence of the patella. *J Bone Joint Surg Am* 55 (1973) 1088–1090.
11. J.L. Beguiristáin, P.D. de Rada, A. Barriga. Nail-patella syndrome: long term evolution. *J Pediatr Orthop B* 12 (2003) 13–16.
12. A.K. Banskota, W. Mayo-Smith, S. Rajbhandari, D.I. Rosenthal. Case report 548: nail-patella syndrome (hereditary onycho-osteodysplasia) with congenital absence of the fibulae. *Skeletal Radiol* 18 (1989) 318–321.
13. M. Letts. Hereditary onycho-osteodysplasia (nail-patella syndrome). A three-generation familial study. *Orthop Rev* 20 (1991) 267–272.